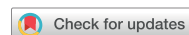

Original Article



A Comparison Study of Cilostazol and Aspirin on Changes in Volume of Cerebral Small Vessel Disease White Matter Changes: Protocol of a Multicenter, Randomized Controlled Trial

Hyun Jeong Han ,¹ Byeong C. Kim ,² Young Chul Youn ,³ Jee Hyang Jeong ,⁴ Jong Hun Kim ,⁵ Jae-Hong Lee ,⁶ Kee Hyung Park ,⁷ Kyung Won Park ,⁸ Eun-Joo Kim ,⁹ Mi Sun Oh ,¹⁰ Yong S. Shim ,¹¹ Hyun Young Park ,¹² Bora Yoon ,¹³ Soo Jin Yoon ,¹⁴ Soo-Jin Cho ,¹⁵ Key Chung Park ,¹⁶ Duk L. Na ,¹⁷ Sun Ah Park ,¹⁸ Jong-Min Lee ,¹⁹ Seong Hye Choi ²⁰

OPEN ACCESS

Received: Aug 20, 2019

Revised: Oct 2, 2019

Accepted: Oct 20, 2019

Correspondence to

Seong Hye Choi

Department of Neurology, Inha University Hospital, 27 Inhang-ro, Jung-gu, Incheon 22332, Korea.

E-mail: seonghye@inha.ac.kr

© 2019 Korean Dementia Association

This is an Open Access article distributed under the terms of the Creative Commons Attribution Non-Commercial License (<https://creativecommons.org/licenses/by-nc/4.0/>) which permits unrestricted non-commercial use, distribution, and reproduction in any medium, provided the original work is properly cited.

ORCID iDs

Hyun Jeong Han

<https://orcid.org/0000-0002-1129-6340>

Byeong C. Kim

<https://orcid.org/0000-0001-6827-6730>

Young Chul Youn

<https://orcid.org/0000-0002-2742-1759>

Jee Hyang Jeong

<https://orcid.org/0000-0001-7945-6956>

Jong Hun Kim

<https://orcid.org/0000-0002-2594-1048>

Jae-Hong Lee

<https://orcid.org/0000-0001-7368-4560>

Kee Hyung Park

<https://orcid.org/0000-0001-6847-6679>

Kyung Won Park

<https://orcid.org/0000-0002-6788-5267>

¹Department of Neurology, Myongji Hospital, Hanyang University College of Medicine, Goyang, Korea

²Department of Neurology, Chonnam National University Medical School, Gwangju, Korea

³Department of Neurology, College of Medicine, Chung-Ang University, Seoul, Korea

⁴Department of Neurology, Ewha Womans University School of Medicine, Seoul, Korea

⁵Department of Neurology, National Health Insurance Service Ilsan Hospital, Goyang, Korea

⁶Department of Neurology, Asan Medical Center, University of Ulsan College of Medicine, Seoul, Korea

⁷Department of Neurology, Gil Medical Center, Gachon University College of Medicine, Incheon, Korea

⁸Department of Neurology, Dong-A University College of Medicine, Busan, Korea

⁹Department of Neurology, Pusan National University Hospital, Pusan National University School of Medicine and Medical Research Institute, Busan, Korea

¹⁰Department of Neurology, Hallym University Sacred Heart Hospital, Hallym University College of Medicine, Anyang, Korea

¹¹Department of Neurology, The Catholic University of Korea Eunpyeong St. Mary's Hospital, Bucheon, Korea

¹²Department of Neurology, Wonkwang University School of Medicine, Iksan, Korea

¹³Department of Neurology, Konyang University College of Medicine, Daejeon, Korea

¹⁴Department of Neurology, Eulji University Hospital, Eulji University School of Medicine, Daejeon, Korea

¹⁵Department of Neurology, Hallym University Dongtan Sacred Heart Hospital, Hallym University College of Medicine, Hwaseong, Korea

¹⁶Department of Neurology, Kyung Hee University School of Medicine, Seoul, Korea

¹⁷Department of Neurology, Samsung Medical Center, Sungkyunkwan University School of Medicine, Seoul, Korea

¹⁸Department of Anatomy and Neurology, Ajou University School of Medicine, Suwon, Korea








¹⁹Department of Biomedical Engineering, Hanyang University, Seoul, Korea

²⁰Department of Neurology, Inha University School of Medicine, Incheon, Korea

ABSTRACT

Background and Purpose: Cerebral small vessel disease (CSVD) is the most common cause of vascular dementia and a major contributor to mixed dementia. CSVD is characterized by progressive cerebral white matter changes (WMC) due to chronic low perfusion and loss of autoregulation. In addition to its antiplatelet effect, cilostazol exerts a vasodilating effect and improves endothelial function. This study aims to compare the effects of cilostazol and aspirin on changes in WMC volume in CSVD.

Methods: The comparison study of Cilostazol and aspirin on cHANGES in volume of cerebral smaLL vEssel disease white matter chaNGEs (CHALLENGE) is a double blind, randomized trial involving 19 hospitals across South Korea. Patients with moderate or severe WMC and

Eun-Joo Kim 
<https://orcid.org/0000-0002-8460-1377>
 Mi Sun Oh 
<https://orcid.org/0000-0002-6741-0464>
 Yong S. Shim 
<https://orcid.org/0000-0001-5642-5401>
 Hyun Young Park 
<https://orcid.org/0000-0003-1394-9453>
 Bora Yoon 
<https://orcid.org/0000-0002-1135-3392>
 Soo Jin Yoon 
<https://orcid.org/0000-0003-4671-6832>
 Soo-Jin Cho 
<https://orcid.org/0000-0002-4053-3763>
 Key Chung Park 
<https://orcid.org/0000-0001-8250-9561>
 Duk L. Na 
<https://orcid.org/0000-0002-0098-7592>
 Sun Ah Park 
<https://orcid.org/0000-0002-3027-3259>
 Jong-Min Lee 
<https://orcid.org/0000-0002-3598-376X>
 Seong Hye Choi 
<https://orcid.org/0000-0002-4180-8626>

Trial Registration

ClinicalTrials.gov Identifier: [NCT01932203](https://clinicaltrials.gov/ct2/show/study/NCT01932203)

Funding

This study was supported by Korea Otsuka Pharmaceutical Company.

Conflicts of Interest

The authors have no financial conflicts of interest.

Author Contributions

Conceptualization: Choi SH. Investigation: Kim BC, Youn YC, Jeong JH, Kim JH, Lee JH, Park KH, Park KW, Kim EJ, Oh MS, Shim YS, Park HY, Yoon B, Yoon SJ, Cho SJ, Park KC, Na DL, Park SA, Choi SH. Writing - original draft: Han HJ. Writing - review & editing: Choi SH.

≥ 1 lacunar infarction detected on brain magnetic resonance imaging (MRI) are eligible; the projected sample size is 254. Participants are randomly assigned to a cilostazol or aspirin group at a 1:1 ratio. Cilostazol slow release 200 mg or aspirin 100 mg are taken once daily for 2 years. The primary outcome measure is the change in WMC volume on MRI from baseline to 104 weeks. Secondary imaging outcomes include changes in the number of lacunes and cerebral microbleeds, fractional anisotropy and mean diffusivity on diffusion tensor imaging, and brain atrophy. Secondary clinical outcomes include all ischemic strokes, all vascular events, and changes in cognition, motor function, mood, urinary symptoms, and disability.

Conclusions: CHALLENGE will provide evidence to support the selection of long-term antiplatelet therapy in CSVD.

Trial Registration: ClinicalTrials.gov Identifier: [NCT01932203](https://clinicaltrials.gov/ct2/show/study/NCT01932203)

Keywords: Cerebral Small Vessel Disease; White Matter; Cilostazol; Clinical Trial

INTRODUCTION

Cerebral small vessel disease (CSVD) is a disorder of the brain's small perforating arterioles, capillaries and venules, which causes various lesions observed on pathological examination, or on brain magnetic resonance imaging (MRI) or computed tomography.¹ Patients with CSVD exhibit many clinical manifestations, including lacunar ischemic stroke,² cognitive impairment, especially affecting executive function,³ depression,⁴ urinary incontinence,⁵ gait disturbance,⁶ and extrapyramidal symptoms.⁷ CSVD is the attributable cause of 25% of strokes, and more than doubles the risk for recurrent stroke.⁸ CSVD is the most common cause of vascular dementia and a major contributor to mixed dementia.⁹ It is, therefore, important to treat CSVD to prevent and/or treat vascular and mixed dementias.

Features of CSVD evident on neuroimaging include recent small subcortical infarcts, lacunes, white matter changes (WMC), enlarged perivascular spaces, cerebral microbleeds (CMBs), and brain atrophy.¹⁰ Increased mean diffusivity (MD) and reduced fraction anisotropy (FA) on diffusion tensor imaging (DTI) are also observed in WMC and normal-appearing white matter (NAWM) in patients with severe WMC.^{11,12} In a previous study, impaired microstructural integrity preceded conversion to WMC visible on conventional neuroimaging.¹¹

The mechanisms that link CSVD to parenchymal damage are heterogeneous. Pathological changes in CSVD have both ischemic and hemorrhagic consequences. Lacunar infarcts can be caused by acute closure of cerebral small blood vessels, and WMC may be due to incomplete infarction or selective necrosis by chronic low perfusion caused by stenosis of small blood vessels.⁹ In addition, disrupted autoregulation and damage to the blood-brain barrier (BBB) could be involved in CSVD.¹³ The endothelium plays a crucial role in processes including the autoregulation of blood flow and function of the BBB.⁹ Derangement of the BBB, however, may begin some years before the first symptoms of ischemic forms of CSVD manifest, and lead to structural, vascular, and perivascular changes in the small vessels of the brain, resulting in edema, enlarged perivascular spaces, and tissue damage.^{9,10,13}

In the Cilostazol for Prevention of Secondary Stroke (CSPS 2) study, cilostazol appeared be superior to aspirin in the prevention of stroke after an ischemic stroke,¹⁴ in which two-

thirds of the subjects experienced lacunar strokes due to CSVD.¹⁴ Cilostazol is a selective phosphodiesterase III inhibitor and inhibits platelet aggregation similar to aspirin.¹⁵ In addition, cilostazol exerts a vasodilating effect,¹⁶ and has the effect of inhibiting proliferation of smooth muscle cells,¹⁷ as well as a favorable effect on re-endothelialization mediated by hepatocyte growth factor¹⁸ and endothelial precursor cells.¹⁹ Therefore, cilostazol may be more effective for CSVD than drugs that exert only an antiplatelet effect.²⁰ If primary outcome is all stroke events in a comparative study of cilostazol and aspirin in CSVD, thousands of subjects will be needed. However, when the primary outcome is a change in WMC on brain MRI, the number of subjects can be significantly reduced.²¹ To the best of our knowledge, there have been no studies comparing the effects of cilostazol and aspirin using changes in WMC volume as the primary outcome measure.

The comparison study of Cilostazol and aspirin on cHAnGES in volume of cerebral smaLL vEssel disease white matter chaNGEs (CHALLENGE) aims to compare changes in WMC volume on MRI between aspirin and cilostazol in patients with CSVD. Our hypothesis is that there will be differences in changes in WMC volume from baseline to 24 months between the cilostazol and aspirin groups.

METHODS

Design

CHALLENGE is a multicenter, double blind, randomized trial with a two parallel-arm design. One arm is assigned to cilostazol as the experimental arm and the other arm is assigned to aspirin as the active comparator using a blinded randomization method. Subject enrollment are performed in 19 hospital neurology clinics across South Korea. This investigator-initiated clinical trial has received funding support from Korea Otsuka Pharmaceutical Co. Ltd. (Seoul, Korea). However, the sponsor are not involved in the study design or operations, such as the selection and management of sites, data management, or the drafting of any manuscripts submitted for publication. The study is conducted in accordance with the International Harmonization Conference guidelines on Good Clinical Practice, and the institutional review board of each center approves the study before initiation. Written informed consent is obtained from all potential subjects before participation in the study. The consent document includes the risks and potential benefits of treatment, the trial process, and alternatives to participation. The trial was registered with Clinical Trials.gov (NCT01932203).

Participants

The inclusion and exclusion criteria are summarized in **Table 1**. Briefly, the inclusion criteria included: 1) age between 50 and 85 years; 2) presence of CSVD based on brain MRI, including moderate or severe WMC (deep WMC \geq grade 2 and periventricular WMC \geq grade 2 according to the modified Fazekas criteria)²² and ≥ 1 lacunar infarction; 3) able to walk to hospital (use of a walker or cane is permissible); and 4) agreement to give the written informed consent. Key exclusion criteria include history of recent cerebral infarction within 3 months and conditions with contraindications to long-term antiplatelet therapy. In addition, patients with cortical infarction or subcortical infarction >1.5 cm in size, Parkinson's disease or Alzheimer's disease (AD), cardioembolic heart disease of high- and medium-risk sources by the Trial of Org 10172 in Acute Stroke Treatment classification,²³ chronic liver disease, chronic renal failure, or specific white matter involving disease, such as multiple sclerosis or sarcoidosis, are excluded. Patients with severe or unstable medical disease that may prevent

Table 1. Inclusion and exclusion criteria

Criteria
Inclusion criteria
1. 50 to 85 years of age
2. Able to walk to the hospital (walker or cane is permissible)
3. Cerebral small vessel disease observed on brain MRI confirmed by the following: presence of ≥1 lacunar infarction (s); and moderate or severe confluent WMC (defined as grade 2 or 3 on the modified Fazekas scale ²²) of periventricular WMC with cap or rims >5 mm and deep subcortical WMC >10 mm in maximum diameter
4. Agreement to give the written informed consent
Exclusion criteria
1. Contraindication (s) to antiplatelets
2. Cardioembolic source
3. Carotid bruit or large cerebral artery stenosis >50%
4. Cortical infarction or subcortical infarction >1.5 cm
5. Bleeding tendency
6. Chronic liver disease (AST or ALT >100 IU/L)
7. Chronic renal disease (creatinine >3.0 mg/dL)
8. Active gastrointestinal ulcer
9. Severe or unstable medical disease that may prevent completion of study requirements (i.e., unstable or severe asthma)
10. Anemia (hemoglobin <10 g/dL) or thrombocytopenia
11. Cardiac pacemaker or contraindication to MRI
12. Pregnancy or breast-feeding
13. Drug or alcohol addiction
14. Any other white matter disease (i.e., multiple sclerosis, sarcoidosis, or brain irradiation), or brain tumor
15. Parkinson's disease, Alzheimer's disease or any other neurodegenerative disease
16. Any hearing or visual impairment that can disturb efficient evaluation of the patient
17. Recent cerebral infarction within 3 months

MRI: magnetic resonance imaging, WMC: white matter changes, AST: aspartate aminotransferase, ALT: alanine aminotransferase.

completion of study requirements, such as recent intracerebral hemorrhage, subdural hematoma, or intraventricular hemorrhage are also excluded.

Randomization

During the screening period, anonymized baseline clinical and neuroimaging data are collected to assess potential eligibility. After the confirmation of inclusion and exclusion criteria, participants are randomly assigned to the cilostazol or aspirin group in a 1:1 ratio. A study identification number generated electronically by a central randomization service is assigned to each patient, and the centralized block randomization, stratified by the center, is performed by the interactive web response system. After randomization, all participants are instructed to take cilostazol slow release (SR) 200 mg in the evening or aspirin 100 mg in the morning once daily, with a simultaneously provided placebo as a double dummy.

Treatment

After randomization, the participants in the cilostazol group take cilostazol SR 200 mg (100 mg [2 capsules]) in the evening and a placebo aspirin tablet in the morning for 104 weeks, and those in the aspirin group take aspirin 100 mg in the morning and placebo cilostazol (2 capsules) in the evening (**Fig. 1**). If a participant experiences an adverse drug reaction (ADR), the drug can be temporarily suspended or reduced at any time during the study period. After the ADR is resolved, the dose can be increased. If a subject is unable to tolerate cilostazol SR 100 mg or aspirin 100 mg, the subject is dropped from the study. Temporary suspension of the trial treatment is permitted for invasive treatments, such as surgery, but cannot exceed two weeks. During the study period, additional anticoagulants or antiplatelet agents (e.g.,

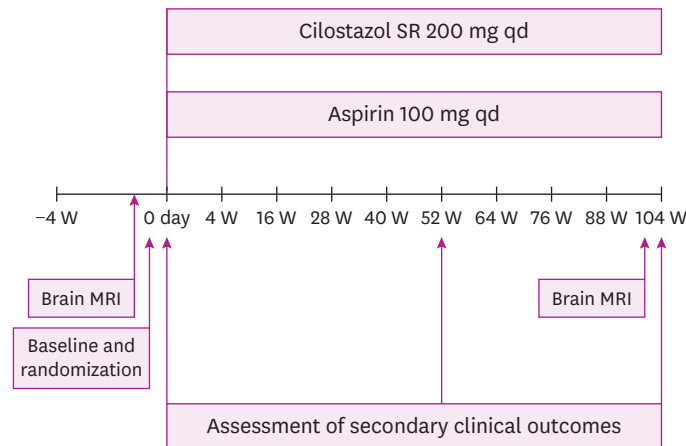


Fig. 1. Trial design flow diagram.

SR: slow release, qd: once per day, W: week, MRI: magnetic resonance imaging.

ticlopidine, clopidogrel, dipyridamole, triflusal), except for antiplatelet agents, which are given as investigational products, are prohibited.

Follow-up

All participants visit four weeks after randomization to assess adverse events and compliance with the study drug. Thereafter, they visit every 12 weeks, up to 88 weeks and, finally, at 104 weeks to assess adverse events and compliance with the study drug. Brain MRI is performed using a 3.0 Tesla magnetic resonance (MR) scanner at baseline or within 4 weeks before baseline, and at week 104. Blood tests, including blood urea nitrogen, creatinine, hemoglobin (Hb), platelets, aspartate aminotransferase, alanine aminotransferase, albumin, glucose, glycated HbA1C (HbA1C), low density lipoprotein-cholesterol, high density lipoprotein-cholesterol, triglycerides, total cholesterol and uric acid, and urine microalbumin to creatinine ratio are evaluated at screening. Other clinical outcome assessments are also performed at baseline, week 52, and week 104 (**Fig. 1**).

Brain MRI examination

Brain MRI data are acquired from all participants at screening and at week 104 using a 3.0 Tesla MR scanner, which captures axial fluid-attenuated inversion recovery (FLAIR) imaging of 2 mm thickness without gap, three-dimensional (3D) T1-weighted imaging, axial T2-weighted imaging, DTI of 2 mm thickness without gap, and gradient echo imaging. The MR scanners used include the Discovery MR 750 and the Signa Hdxt (GE Healthcare, Milwaukee, WI, USA), the Achieva (Philips Healthcare, Andover, MA, USA), and the Skyra, Verio, and Trio Tim (Siemens, Washington, D.C., USA). The MRI protocols are based on the AD Neuroimaging Initiative phase 2 MRI protocols.²⁴

MRI is performed using a standardized protocol provided to the centers. Prior to starting MRI acquisition in participants, centers are requested to test the protocol with a volunteer. Images are then sent to the laboratory at Hanyang University, a MRI coordinating center that provides the required certificates of quality. Once the quality of images is authorized, centers are requested to send the acquired images of a participant each time. Upon reception by the MRI coordinating center, quality controls of the acquired images are undertaken in order to detect whether a participant needed rescanning. The analysis of the images will be conducted at the laboratory of Hanyang University. To measure the volume of WMC, WMC on the FLAIR

images will be segmented using the FMRIB Automatic Segmentation Tool (FAST) of the FMRIB Software Library (<http://www.fmrib.ox.ac.uk/fsl/>). The FAST segmentation tool is based on a hidden Markov random field model and an associated expectation-maximization algorithm.²⁵ Hyperintensity signal artifacts included in the WMC mask will be edited manually using ITK-SNAP program (<http://www.itksnap.org>).

Outcome measures

The primary outcome measure is change in WMC volume on brain FLAIR imaging from baseline to 104 weeks. Secondary imaging outcomes include changes in MD and FA for WMC and NAWM on DTI, number of lacunes, number of CMBs, brain volume, and cortical thickness. Secondary outcomes include all ischemic stroke events, including cerebral infarction and transient ischemic attack (TIA), and all vascular events including ischemic stroke, TIA, myocardial infarction, angina pectoris, cerebral venous thrombosis, pulmonary embolism, symptomatic deep vein thrombosis, symptomatic peripheral artery occlusion, other vascular occlusion, and any revascularization procedure. Changes in cognition, motor function, mood, urinary symptoms, and disability between the cilostazol and aspirin groups are also compared as secondary clinical outcomes. Detailed secondary outcome measures are summarized in **Table 2**.

Sample size estimates

The primary null hypothesis is that there will be no differences in change in WMC volume from baseline to study end between the cilostazol and aspirin groups. In a previous study, changes in WMC volume percentage from baseline to approximately 2 years were $0.11\% \pm 0.84\%$ and $0.39\% \pm 0.48\%$ for the aspirin and cilostazol groups, respectively.¹² Based on a power of 0.8 for

Table 2. Primary and secondary outcome measures

Instrument or method	
Primary outcome measure	
Imaging	Change in the volume of WMC on brain MRI
Secondary outcome measure	
Imaging	Mean diffusivity and fraction anisotropy on WMC and NAWM Number of lacunes Number of cerebral microbleeds Brain volume Cortical thickness
Vascular event	All ischemic stroke including cerebral infarction and TIA All vascular events, including ischemic stroke, TIA, myocardial infarction, angina pectoris, cerebral venous thrombosis, pulmonary embolism, symptomatic deep vein thrombosis, symptomatic peripheral artery occlusion, other vascular occlusion, and any revascularization procedure
Cognition	Mini-Mental State Examination ²⁶ Neurocognitive tests including Seoul Verbal Learning Test, 15-item Boston Naming Test, Rey-Osterrieth Complex figure copy, animal fluency, controlled oral word association test, Stroop Color and Word test, Digit Symbol Substitution Test, and Trail Making Test Parts A and B Clinical Dementia Rating scale-Sum of Boxes ²⁷
Mood	Geriatric Depression Scale-15 items ²⁸ Caregiver-Administered Neuropsychiatric Inventory ²⁹
Motor performance	Pyramidal and Extrapyramidal Scale ³⁰ Timed "Up & Go" test ³¹
Urinary symptoms	King's Health Questionnaire ³²
Function	Bayer Activities of Daily Living ³³ Barthel Index ³⁴

WMC: white matter changes, MRI: magnetic resonance imaging, NAWM: normal-appearing white matter, TIA: transient ischemic attack.

detecting a significant difference ($p=0.05$ [two-sided]) using a two-sample t -test using PASS 2008, 95 patients were required for each study group. Assuming a discontinuation rate of 25%,¹⁴ the calculated sample size is 254, with 127 participants in each group.

Statistical analysis

The end-points will be assessed using a modified intention-to-treat (ITT) population, defined as all randomized patients who receive at least one dose of study medication and undergo a baseline evaluation and at least one post-baseline assessment after beginning the study medication. Additional analyses on a per-protocol population will be also performed. The conclusion of the trial will use the modified ITT analysis. Analysis of covariance will be used to compare changes in imaging parameters from baseline to study end between the cilostazol and aspirin groups. Cox proportional hazard models will be used to calculate the hazard ratio of all ischemic stroke or all vascular events and corresponding 95% confidence intervals for the cilostazol group compared with the aspirin group. Linear mixed models will be used to compare changes in other secondary clinical outcomes between the cilostazol and aspirin groups. The safety analysis population will comprise participants who receive at least one dose of study medication and undergo at least one safety evaluation after baseline. The chi-squared test will be used to compare the prevalence of adverse events between the cilostazol and aspirin groups.

Preplanned substudies

Participants are tested to assess apolipoprotein E genotyping, renin-angiotensin system gene polymorphism (ACE I/D, AGT M235T), and C-peptide. Blood levels of markers of endothelial function, including von Willebrand factor, tissue factors, intercellular adhesion molecule-1 and vascular cell adhesion molecule-1 will be tested, as will anti-inflammatory molecules including interleukin (IL)-6, IL-18, and high sensitivity C-reactive protein. The risk and protective factors associated with progression of imaging parameters or clinical symptoms of CSVD will be evaluated.

DISCUSSION

CSVD is associated with stroke, vascular parkinsonism, and cognitive impairment.³⁵ CSVD is also the most common accompanying pathology in AD.³⁶ Mixed brain pathologies are common in most cases of dementia and in cognitively normal elderly individuals.^{36,37} In a previous study, individuals with multiple pathologies were almost three times more likely to experience dementia compared with those with a single pathological diagnosis.³⁶ It is important to control CSVD to prevent or delay the onset of dementia in patients with AD or other neurodegenerative disease (s) accompanied by CSVD. Therefore, this study aims to investigate antiplatelet agents that may be more effective at inhibiting the progression of CSVD. Aspirin is a popular drug used to treat patients with CSVD. Cilostazol exerts effects of vasodilation, inhibition of smooth muscle proliferation, endothelial protection, as well as an antiplatelet effect.¹⁵⁻²⁰ Therefore, cilostazol may be more effective in patients with CSVD than aspirin.

Most patients with CSVD have no clinical history of stroke. They usually experience slowly progressive cognitive impairment or neurological symptoms.³⁸ Therefore, it may be inappropriate to consider symptomatic stroke incidence as a primary outcome for drugs that may inhibit the progression of CSVD. WMC is typically interpreted as a surrogate of CSVD.³⁹

A recent study showed that advanced WMC in Asian patients with ischemic stroke and CSVD burden was associated with an increased risk of recurrent stroke.⁴⁰ Overall, longitudinal studies have reported annual increases in WMC volume ranging from 4.4% to 37.2%.⁴¹ Although the subject pool in that study was not limited to those with CSVD, changes in WMC volume determined quantitatively using a semi-automatic method was used as an outcome in a post hoc analysis to investigate the effect of statins on WMC progression.⁴² Changes in WMC volume, graded according to a visual rating scale, were also used as an outcome in a study investigating the effects of blood pressure lowering on cerebral WMC.⁴³ However, there have been no studies investigating the effect of any antiplatelet drugs on WMC progression in patients with CSVD. To our knowledge, therefore, the present study is the first to compare cilostazol and aspirin in terms of changes in WMC volume as the primary outcome measure in patients with CSVD.

In this study, we will investigate the effects of cilostazol and aspirin on all CSVD brain imaging markers by measuring changes in the number of lacunes, number of CMBs, MD and FA for WMC and NAWM on DTI, brain volume, and cortical thickness. More specifically, no study has evaluated the effect of any antiplatelet on brain atrophy and ultrastructural changes in white matter using DTI in patients with CSVD. Brain atrophy is an important measure to assess the burden of vascular damage in the brain, and atrophy is believed to mediate the effects of vascular lesions on cognition in CSVD.¹⁰ MD and FA for WMC or NAWM on DTI are correlated with cognitive impairment and disability, and cognitive and functional decline are associated with aggravated ultrastructural changes in white matter.^{11,12} The number of incident new lacunes was related to cognitive decline in the Leukoaraiosis and Disability Study.⁴⁴ Furthermore, the presence of multiple CMBs was associated with cognitive impairment in a previous cross-sectional study.⁴⁵ Therefore, to fully evaluate CSVD progression, these imaging markers must be evaluated.

In addition to stroke recurrence, patients with CSVD experience a variety of symptoms, including cognitive impairment, depression, gait disturbance, extrapyramidal symptoms and signs, urinary incontinence, and disability. However, previous studies have only compared the efficacy of cilostazol and aspirin for the prevention of recurrent stroke or major vascular events.^{14,46} In this trial, we plan to evaluate all CSVD symptoms as secondary outcomes. These clinical evaluations are aimed at investigating differences between the two drugs with regard to clinical symptoms that affect the daily lives and quality of life of the participants.

In conclusion, the CHALLENGE trial is the first to compare cilostazol and aspirin in terms of changes in WMC volume as the primary outcome, and changes in other CSVD imaging markers and various CSVD symptoms and vascular events as secondary outcomes. Our results will inform clinical decisions regarding the choice of long-term antiplatelet therapy in patients with CSVD, which is currently controversial in clinical practice.

REFERENCES

1. DeBette S, Markus HS. The clinical importance of white matter hyperintensities on brain magnetic resonance imaging: systematic review and meta-analysis. *BMJ* 2010;341:c3666.
[PUBMED](#) | [CROSSREF](#)
2. Vermeer SE, Longstreth WT Jr, Koudstaal PJ. Silent brain infarcts: a systematic review. *Lancet Neurol* 2007;6:611-619.
[PUBMED](#) | [CROSSREF](#)

3. Rensma SP, van Sloten TT, Launer LJ, Stehouwer CD. Cerebral small vessel disease and risk of incident stroke, dementia and depression, and all-cause mortality: A systematic review and meta-analysis. *Neurosci Biobehav Rev* 2018;90:164-173.
[PUBMED](#) | [CROSSREF](#)
4. van Agtmaal MJ, Houben AJ, Pouwer F, Stehouwer CD, Schram MT. Association of microvascular dysfunction with late-life depression: a systematic review and meta-analysis. *JAMA Psychiatry* 2017;74:729-739.
[PUBMED](#) | [CROSSREF](#)
5. Cannistraro RJ, Badi M, Eidelman BH, Dickson DW, Middlebrooks EH, Meschia JF. CNS small vessel disease: a clinical review. *Neurology* 2019;92:1146-1156.
[PUBMED](#) | [CROSSREF](#)
6. Kim YJ, Kwon HK, Lee JM, Cho H, Kim HJ, Park HK, et al. Gray and white matter changes linking cerebral small vessel disease to gait disturbances. *Neurology* 2016;86:1199-1207.
[PUBMED](#) | [CROSSREF](#)
7. van der Holst HM, van Uden IW, Tuladhar AM, de Laat KF, van Norden AG, Norris DG, et al. Cerebral small vessel disease and incident parkinsonism: The RUN DMC study. *Neurology* 2015;85:1569-1577.
[PUBMED](#) | [CROSSREF](#)
8. Nam KW, Kwon HM, Lim JS, Han MK, Nam H, Lee YS. The presence and severity of cerebral small vessel disease increases the frequency of stroke in a cohort of patients with large artery occlusive disease. *PLoS One* 2017;12:e0184944.
[PUBMED](#) | [CROSSREF](#)
9. Pantoni L. Cerebral small vessel disease: from pathogenesis and clinical characteristics to therapeutic challenges. *Lancet Neurol* 2010;9:689-701.
[PUBMED](#) | [CROSSREF](#)
10. Wardlaw JM, Smith C, Dichgans M. Mechanisms of sporadic cerebral small vessel disease: insights from neuroimaging. *Lancet Neurol* 2013;12:483-497.
[PUBMED](#) | [CROSSREF](#)
11. van Leijssen EM, Bergkamp MI, van Uden IW, Ghafoorian M, van der Holst HM, Norris DG, et al. Progression of white matter hyperintensities preceded by heterogeneous decline of microstructural integrity. *Stroke* 2018;49:1386-1393.
[PUBMED](#) | [CROSSREF](#)
12. Ryoo NY, Yoon B, Yoon CW, Ahn J, Choi JY, Lim MK, et al. Diffusion tensor imaging changes correlate with clinical progression in vascular mild cognitive impairment and vascular dementia of subcortical type. *Dement Neurocogn Disord* 2013;12:61-71.
[CROSSREF](#)
13. Wardlaw JM, Doubal F, Armitage P, Chappell F, Carpenter T, Muñoz Maniega S, et al. Lacunar stroke is associated with diffuse blood-brain barrier dysfunction. *Ann Neurol* 2009;65:194-202.
[PUBMED](#) | [CROSSREF](#)
14. Shinohara Y, Katayama Y, Uchiyama S, Yamaguchi T, Handa S, Matsuoka K, et al. Cilostazol for prevention of secondary stroke (CSPS 2): an aspirin-controlled, double-blind, randomised non-inferiority trial. *Lancet Neurol* 2010;9:959-968.
[PUBMED](#) | [CROSSREF](#)
15. Gurbel PA, Tantry US. Combination antithrombotic therapies. *Circulation* 2010;121:569-583.
[PUBMED](#) | [CROSSREF](#)
16. de Donato G, Setacci F, Mele M, Giannace G, Galzerano G, Setacci C. Restenosis after coronary and peripheral intervention: efficacy and clinical impact of cilostazol. *Ann Vasc Surg* 2017;41:300-307.
[PUBMED](#) | [CROSSREF](#)
17. Morishita R. A scientific rationale for the CREST trial results: evidence for the mechanism of action of cilostazol in restenosis. *Atheroscler Suppl* 2005;6:41-46.
[PUBMED](#) | [CROSSREF](#)
18. Aoki M, Morishita R, Hayashi S, Jo N, Matsumoto K, Nakamura T, et al. Inhibition of neointimal formation after balloon injury by cilostazol, accompanied by improvement of endothelial dysfunction and induction of hepatocyte growth factor in rat diabetes model. *Diabetologia* 2001;44:1034-1042.
[PUBMED](#) | [CROSSREF](#)
19. Kawabe-Yako R, Ii M, Masuo O, Asahara T, Itakura T. Cilostazol activates function of bone marrow-derived endothelial progenitor cell for re-endothelialization in a carotid balloon injury model. *PLoS One* 2011;6:e24646.
[PUBMED](#) | [CROSSREF](#)
20. Edrissi H, Schock SC, Cadonic R, Hakim AM, Thompson CS. Cilostazol reduces blood brain barrier dysfunction, white matter lesion formation and motor deficits following chronic cerebral hypoperfusion. *Brain Res* 2016;1646:494-503.
[PUBMED](#) | [CROSSREF](#)

21. Schmidt R, Berghold A, Jokinen H, Gouw AA, van der Flier WM, Barkhof F, et al. White matter lesion progression in LADIS: frequency, clinical effects, and sample size calculations. *Stroke* 2012;43:2643-2647.
[PUBMED](#) | [CROSSREF](#)
22. Fazekas F, Chawluk JB, Alavi A, Hurtig HI, Zimmerman RA. MR Signal abnormalities at 1.5T in Alzheimer's dementia and normal aging. *AJR Am J Roentgenol* 1987;149:351-356.
[PUBMED](#) | [CROSSREF](#)
23. Adams HP Jr, Bendixen BH, Kappelle LJ, Biller J, Love BB, Gordon DL, et al. Classification of subtype of acute ischemic stroke. Definitions for use in a multicenter clinical trial. TOAST. Trial of Org 10172 in Acute Stroke Treatment. *Stroke* 1993;24:35-41.
[PUBMED](#) | [CROSSREF](#)
24. Beckett LA, Donohue MC, Wang C, Aisen P, Harvey DJ, Saito N, et al. The Alzheimer's disease neuroimaging initiative phase 2: increasing the length, breadth, and depth of our understanding. *Alzheimers Dement* 2015;11:823-831.
[PUBMED](#) | [CROSSREF](#)
25. Zhang Y, Brady M, Smith S. Segmentation of brain MR images through a hidden Markov random field model and the expectation-maximization algorithm. *IEEE Trans Med Imaging* 2001;20:45-57.
[PUBMED](#) | [CROSSREF](#)
26. Han C, Jo SA, Jo I, Kim E, Park MH, Kang Y. An adaptation of the Korean mini-mental state examination (K-MMSE) in elderly Koreans: demographic influence and population-based norms (the AGE study). *Arch Gerontol Geriatr* 2008;47:302-310.
[PUBMED](#) | [CROSSREF](#)
27. Choi SH, Lee BH, Kim S, Hahm DS, Jeong JH, Yoon SJ, et al. Interchanging scores between clinical dementia rating scale and global deterioration scale. *Alzheimer Dis Assoc Disord* 2003;17:98-105.
[PUBMED](#) | [CROSSREF](#)
28. Bae JN, Cho MJ. Development of the Korean version of the Geriatric Depression Scale and its short form among elderly psychiatric patients. *J Psychosom Res* 2004;57:297-305.
[PUBMED](#) | [CROSSREF](#)
29. Kang SJ, Choi SH, Lee BH, Jeong Y, Hahm DS, Han IW, et al. Caregiver-administered neuropsychiatric inventory (CGA-NPI). *J Geriatr Psychiatry Neurol* 2004;17:32-35.
[PUBMED](#) | [CROSSREF](#)
30. Kim SH, Seo SW, Go SM, Chin J, Lee BH, Lee JH, et al. Pyramidal and extrapyramidal scale (PEPS): a new scale for the assessment of motor impairment in vascular cognitive impairment associated with small vessel disease. *Clin Neurol Neurosurg* 2011;113:181-187.
[PUBMED](#) | [CROSSREF](#)
31. Podsiadlo D, Richardson S. The timed "Up & Go": a test of basic functional mobility for frail elderly persons. *J Am Geriatr Soc* 1991;39:142-148.
[PUBMED](#) | [CROSSREF](#)
32. Oh SJ, Park HG, Paick SH, Park WH, Choo MS. Translation and Linguistic validation of Korean version of the king's health questionnaire instrument. *Korean J Urol* 2005;46:438-450.
33. Choi SH, Na DL, Lee BH, Kang SJ, Ha CK, Han SH, et al. Validation of the Korean version of the Bayer activities of daily living scale. *Hum Psychopharmacol* 2003;18:469-475.
[PUBMED](#) | [CROSSREF](#)
34. Mahoney FI, Barthel DW. Functional evaluation: the Barthel Index. *Md State Med J* 1965;14:61-65.
[PUBMED](#)
35. Wardlaw JM, Smith C, Dichgans M. Small vessel disease: mechanisms and clinical implications. *Lancet Neurol* 2019;18:684-696.
[PUBMED](#) | [CROSSREF](#)
36. Sonnen JA, Santa Cruz K, Hemmy LS, Woltjer R, Leverenz JB, Montine KS, et al. Ecology of the aging human brain. *Arch Neurol* 2011;68:1049-1056.
[PUBMED](#) | [CROSSREF](#)
37. Schneider JA, Arvanitakis Z, Bang W, Bennett DA. Mixed brain pathologies account for most dementia cases in community-dwelling older persons. *Neurology* 2007;69:2197-2204.
[PUBMED](#) | [CROSSREF](#)
38. Erkinjuntti T, Inzitari D, Pantoni L, Wallin A, Scheltens P, Rockwood K, et al. Research criteria for subcortical vascular dementia in clinical trials. *J Neural Transm Suppl* 2000;59:23-30.
[PUBMED](#) | [CROSSREF](#)
39. Alber J, Alladi S, Bae HJ, Barton DA, Beckett LA, Bell JM, et al. White matter hyperintensities in vascular contributions to cognitive impairment and dementia (VCID): knowledge gaps and opportunities. *Alzheimers Dement (N Y)* 2019;5:107-117.
[PUBMED](#) | [CROSSREF](#)

40. Park JH, Heo SH, Lee MH, Kwon HS, Kwon SU, Lee JS, et al. White matter hyperintensities and recurrent stroke risk in patients with stroke with small-vessel disease. *Eur J Neurol* 2019;26:911-918.
[PUBMED](#) | [CROSSREF](#)
41. Jorgensen DR, Shaaban CE, Wiley CA, Gianaros PJ, Mettenberg J, Rosano C. A population neuroscience approach to the study of cerebral small vessel disease in midlife and late life: an invited review. *Am J Physiol Heart Circ Physiol* 2018;314:H1117-H1136.
[PUBMED](#) | [CROSSREF](#)
42. Mok VC, Lam WW, Fan YH, Wong A, Ng PW, Tsoi TH, et al. Effects of statins on the progression of cerebral white matter lesion: Post hoc analysis of the ROCAS (Regression of Cerebral Artery Stenosis) study. *J Neurol* 2009;256:750-757.
[PUBMED](#) | [CROSSREF](#)
43. Dufouil C, Chalmers J, Coskun O, Besançon V, Boussier MG, Guillon P, et al. Effects of blood pressure lowering on cerebral white matter hyperintensities in patients with stroke: the PROGRESS (Perindopril Protection Against Recurrent Stroke Study) Magnetic Resonance Imaging Substudy. *Circulation* 2005;112:1644-1650.
[PUBMED](#) | [CROSSREF](#)
44. Jokinen H, Gouw AA, Madureira S, Ylikoski R, van Straaten EC, van der Flier WM, et al. Incident lacunes influence cognitive decline: the LADIS study. *Neurology* 2011;76:1872-1878.
[PUBMED](#) | [CROSSREF](#)
45. Qiu C, Cotch MF, Sigurdsson S, Jonsson PV, Jonsdottir MK, Sveinbjrnsdottir S, et al. Cerebral microbleeds, retinopathy, and dementia: the AGES-Reykjavik Study. *Neurology* 2010;75:2221-2228.
[PUBMED](#) | [CROSSREF](#)
46. Kim BJ, Lee EJ, Kwon SU, Park JH, Kim YJ, Hong KS, et al. Prevention of cardiovascular events in Asian patients with ischaemic stroke at high risk of cerebral haemorrhage (PICASSO): a multicentre, randomised controlled trial. *Lancet Neurol* 2018;17:509-518.
[PUBMED](#) | [CROSSREF](#)