Print ISSN 1738-1495 / On-line ISSN 2384-0757
Dement Neurocogn Disord 2016;15(2):55-58 / http://dx.doi.org/10.12779/dnd.2016.15.2.55

DND

CASE REPORT

Corticobasal Degeneration Presenting as Non-Fluent/ Agrammatic Primary Progressive Aphasia: A Case Report

Ji Sun Kim, Geum Bong Lee, Yun Jeong Hong, Kyung Won Park

Department of Neurology, Cognitive Disorders and Dementia Center, College of Medicine, Dong-A University, Busan, Korea

Background Non-fluent agrammatic primary progressive aphasia (naPPA) is characterized by progressive non-fluent speech disorder and might be associated with taupathy such as corticobasal degeneration (CBD) and progressive supranuclear palsy. We report a case of overlap syndrome presented with language impairment, and diagnosed as naPPA with possible CBD.

Case Report A 58-year-old woman visited a memory and dementia clinic, with a 10-month history of progressive language disturbance. She was diagnosed as naPPA and overlapping CBD, based on the clinical features and neuroimaging findings including florbetaben PET.

Conclusions naPPA is pathologically caused by taupathy, and might progress to asymmetrical parkinsonism and apraxia, suggestive of CBD. Overlapping clinical features in our case represent various phenotypes of taupathy.

Key Words non-fluent agrammatic primary progressive aphasia, taupathy, corticobasal degeneration.

Received: May 31, 2016 **Revised:** June 15, 2016 **Accepted:** June 15, 2016

Correspondence: Kyung Won Park, MD, PhD, Department of Neurology, Cognitive Disorders and Dementia Center, College of Medicine, Dong-A University, 26 Daesingongwon-ro, Seo-gu, Busan 49201, Korea
Tel: +82-51-240-2966, **Fax:** +82-51-240-2560, **E-mail:** neuropark@dau.ac.kr

INTRODUCTION

Frontotemporal lobal degeneration (FTLD) is the third most common form in patients with dementia. There are three subtypes of FTLD: behavioral variant FTD, semantic variant primary progressive aphasia, and non-fluent agrammatic primary progressive aphasia (naPPA); each account for 55%, 20%, and 25% of all FTLD cases.[1] Among them, naPPA is characterized by non-fluent speech disorder, which is preceded with a grammatical error rather than other cognitive disorders.[1-3] It is mostly known to be associated with taupathy[4] including corticobasal degeneration (CBD). The main clinical symptoms of CBD are asymmetrical rigidity, apraxia, cortical dysfunction (alien limb phenomenon, cortical sensory loss, myoclonus), and basal nucleus dysfunction (limb dystonia, bradykinesia, tremor). These symptoms are often manifested in patients with naPPA.[5,6] Here, we report a case who visited us with language impairment, and was diagnosed as naPPA with CBD.

This is an Open Access article distributed under the terms of the Creative Commons Attribution Non-Commercial License (http://creativecommons.org/licenses/by-nc/3.0) which permits unrestricted non-commercial use, distribution, and reproduction in any medium, provided the original work is properly cited.

CASE REPORT

A 58-year-old female visited the Cognitive Disorders and Dementia clinic in March 2016, with a 10-month history of gradually progressive language disturbance. The initial symptoms appeared 4 years ago, when the patient started talking gibberish during conversations at work, without any perception. These events caused some trouble with her colleagues, and lead her to quit the job. Recently, 10 months ago, her family found she accidentally said wrong but similar words in the middle of conversations. The disease was gradually worsened. From 6 months ago, she also began complaining of having trouble in reading. In recent a few months, her speech and behavior had begun to slow. In addition, memory deterioration was observed since the past 4 months, and she intermittently cried alone. Two months prior to the visit, she could speak only one or two words, but was unable to construct complex sentences. She spoke less than before, and almost didn't

Copyright © 2016 Korean Dementia Association

talk. She was taking anti-hypertensive drugs without having any specific family history. She had no past history of smoking and alcoholism.

Neurological examination during the first visit revealed right upper and lower limbs bradykinesia, mild rigidity in both sides of upper limbs, and ideomotor apraxia on both sides. The arm swing was reduced during walking. There were no symptoms of rigidity, myoclonus, alien hand, or cortical sensory loss. There were no abnormalities in eye movement and postural instability. Fluency of speaking was very poor, and she frequently answered "Don't know" to complex instructions. Her repetition was impaired to some long sentence.

For overall evaluation of patient's cognitive impairment, neuropsychological assessment and Korean version of Western aphasia battery was carried out on the second day of hospitalization. She had 6 years of education and was right-handed. She achieved 7 point in the Korean version of Mini-Mental State Examination. In most of the tests such as Backward digit span, Seoul verbal learning test, Rey complex figure test (RCFT) copy, RCFT recall, controlled oral word association test (COWAT), and Stroop test, she was unable to understand the instructions, or got low grades (Table 1). In the results of the K-WAB, the fluency score was 14/20 (61 percentile), and slow, effortful and hesitant speech were accompanied with agrammatism and intermittent phonemic paraphasia. The comprehension score was 128/200 (56 percentile). The score was relatively lower than the fluency score, but she had comprehension disabilities about grammatically complex instructions during the command performance test and the Yes/No test, while performed well in simple instructions. The Naming score

Table 1. Neuropsychological tests results of the patient

Cognitive domain	Neuropsychological tests	Results (2016.4)
Attention	Forward digit span	4 (9.58 percentile)
	Backward digit span	0 (<0.01 percentile)
Language & related function	Spontaneous speech	Non-fluent
	Auditory comprehension	Abnormal
	Repetition	8 (<5 percentile)
	Naming (K-BNT)	27/60 (0.06 percentile)
	Reading	Abnormal
	Writing	Abnormal
	Calculation	0 (<5 percentile)
	Finger naming	Abnormal
	Right-left disorientation	Abnormal
	Body part identification	Abnormal
	Praxis	0 (<5 percentile)
Visuospatial function	RCFT copy score	0 (<0.01 percentile)
Memory	SVLT immediate recall	2 (<0.01 percentile)
	SVLT delayed recall	0 (0.15 percentile)
	SVLT recognition	66.67 (0.42 percentile)
	RCFT immediate recall	0 (1.50 percentile)
	RCFT delayed recall	0 (0.96 percentile)
	RCFT recognition	54.17 (0.02 percentile)
Frontal/executive function	Motor impersistence	Normal
	Contrasting program	1 (<5 percentile)
	Go-No-Go test	1 (<5 percentile)
	Fist-edge-palm	Abnormal
	Alternating square and triangle	Perseveration
	Lulia loop	Deformed
	Semantic word fluency	1 (<0.01 percentile)
	Phonemic word fluency	0 (0.56 percentile)
	Stroop test: word reading	4.80 (<0.01 percentile)
	Stroop test: color reading	Uncheckable

K-BNT: Korean version of Boston Naming Test, RCFT: Rey Complex Figure Test, SVLT: Seoul verbal learning test.

was 54/100 (66 percentile) and there was limited response at the COWAT, sentence completion, and sentence response. The repetition score was 44/100 (36 percentile).

Brain MRI showed left parieto-temporal cortical atrophy (Fig. 1A). F-18 fluorodeoxyglucose positron emission tomography showed diffuse hypometabolism in the left fronto-parieto-temporo-limbic lobes, and in the left striatum & thalamus (Fig. 1B). In addition, the F-18 FP-CIT PET showed a decrease of uptake in the left striatum. Subsequent evaluation by F-18 florbetaben PET revealed brain amyloid plaque load score 1 (negative finding) (Fig. 2), and it confirmed the beta amyloid deposition, which represents Alzheimer's disease (AD)-related pathology was not combined.

DISCUSSION

naPPA is a progressive neurodegenerative condition characterized by slow, effortful, and non-fluent speech in the early stage. Patients show symptoms of reduced words per minutes, grammatical simplification, and errors in grammatical comprehension and expression. Mutism is observed when the symptoms are more progressed.[2] Left perisylvian area (inferior frontal and anterior-superior temporal) atrophy are observed in structural neuroimaging studies, and hypometabolism/hy-

Fig. 1. Brain MRI scan and fluorodeoxyglucose positron emission tomography (FDG-PET) scan of the patient. A: Brain MRI images showing diffuse cerebral atrophy, particularly in the left parietal cortex. B: FDG-PET images showing hypometabolism in the diffuse cortical areas, particularly in the left frontal, temporal, and parietal lobes.

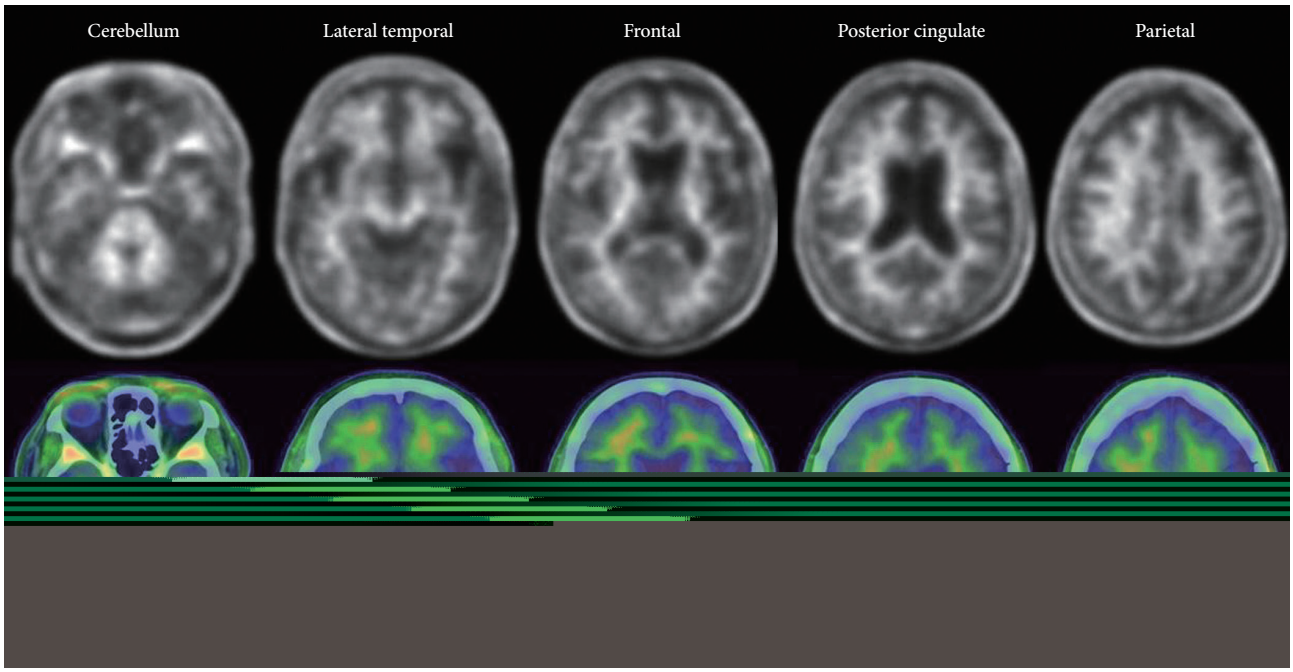

Fig. 2. Florbetaben positron emission tomography (PET) scan of the patient. Florbetaben PET scans were regarded as brain amyloid plaque load score 1 representing negative for β-amyloid uptake.