Print ISSN 1738-1495 / On-line ISSN 2384-0757
Dement Neurocogn Disord 2015;14(1):48-51 / http://dx.doi.org/10.12779/dnd.2015.14.1.48

DND

CASE REPORT

Reversible Amygdala and Parahippocampal Lesions of Brain ^{18}Fluorodeoxy Glucose-Positron Emission Tomography in Neuropsychiatric Systemic Lupus Erythematosus

Do Young Yoon, Doo Yong Park, Subin Lee, Jee Young Kim, Hyun Jeong Han, Eun Jung Kim

Department of Neurology, Myongji Hospital, Seonam University College of Medicine, Goyang, Korea

Background Systemic lupus erythematosus (SLE) is an autoimmune disease that is a significant source of morbidity and mortality when it manifests in the central nervous system. The early detection and treatment of neuropsychiatric SLE (NPSLE) is very important, but a confirmative diagnostic tool has yet to be developed.

Case Report We report here a case of neuropsychiatric manifestations in a patient that were associated with SLE, and evidence of reversal of bilateral amygdala and parahippocampal lesions in the brain revealed by ^{18}fluorodeoxy glucose-positron emission tomography.

Conclusions We are suggestive of ^{18}fluorodeoxy glucose-positron emission tomography appear to be more sensitive in detecting subtle brain changes in NPSLE.

Key Words systemic lupus erythematosus, neuropsychiatric manifestations, brain ^{18}fluorodeoxy glucose-positron emission tomography.

Received: February 2, 2015 **Revised:** March 10, 2015 **Accepted:** March 10, 2015

Correspondence: Hyun Jeong Han, MD, PhD, Department of Neurology, Myongji Hospital, Seonam University College of Medicine, 55 Hwasu-ro 14beon-gil, Deogyang-gu, Goyang 412-826, Korea
Tel: +82-31-810-5403, **Fax:** +82-31-969-0500, **E-mail:** neurohan5403@gmail.com

INTRODUCTION

A diversity of neurologic and psychiatric symptoms in systemic lupus erythematosus (SLE) are reported to occur in 14–75% of patients either prior to the diagnosis or during the course of their illness.[1] The involvement of the central nervous system (CNS) in SLE is a serious but potentially treatable illness, yet SLE still presents a very difficult diagnostic challenge. Neuropsychiatric involvement in SLE (NPSLE) appears to be caused by complex pathologic processes attributed to autoantibody mediated neuronal or vascular injury, intrathecal production of inflammatory cytokines, and disruption of the blood-brain-barrier (BBB).[2] The frequency of NPSLE varies widely, depending on the type of manifestations and the method used for evaluation. The role of the different neuroimaging modalities in the diagnosis and evaluation of disease activities of NPSLE is still very controversial. Magnetic resonance imaging (MRI) remains the gold standard for the non-invasive assessment of NPSLE but there are limitations with its sensitivity and specificity. Single photon emission computed tomography (SPECT) or positron emission tomography (PET) have been found to be useful for early identification of blood-flow or metabolic abnormalities of NPSLE, but they lack spatial resolution. The quantification of change is straightforward.[3,4] In this paper we report about brain PET findings in a young woman with NPSLE who first presented with amnesia and anosmia as neurological symptoms.

CASE REPORT

A 20-year-old right-handed female came to the emergency room, complaining about anosmia, a headache and a mild fever. These symptoms had suddenly started 7 days previous and

ⓒ This is an Open Access article distributed under the terms of the Creative Commons Attribution Non-Commercial License (http://creativecommons.org/licenses/by-nc/3.0) which permits unrestricted non-commercial use, distribution, and reproduction in any medium, provided the original work is properly cited.

 Copyright © 2015 Korean Dementia Association

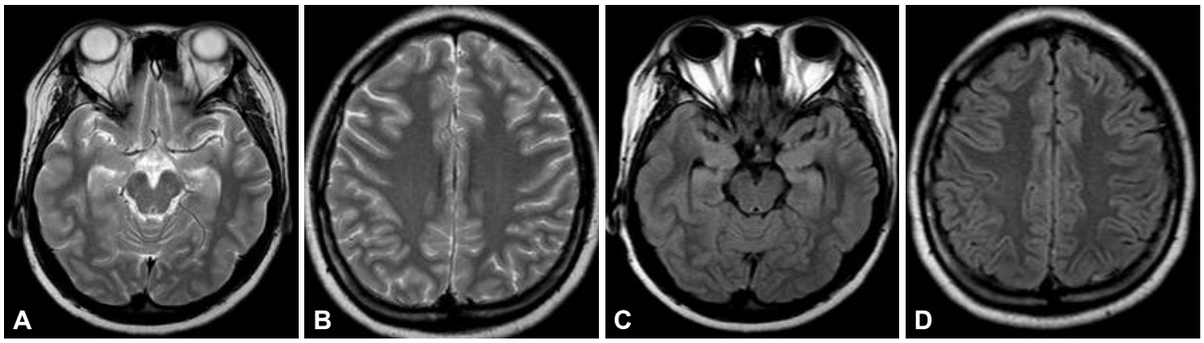

Fig. 1. Brain magnetic resonance imaging on admission. T2-weighted image (A and B), fluid-attenuated inversion recovery (C and D) image showed unremarkable findings.

Table 1. Results of memory and frontal executive function tests

	On admission (%ile)	Three months later (%ile)
Memory		
Verbal memory (K-AVLT)		
Immediate recall	14/75 (1)	33/75 (16)
Delay recall	0/15 (0.05)	4/15 (0.1)
Recognition	5/15 (0.05)	11/15 (2)
Visual memory		
Immediate recall	0/36 (0.05)	13/36 (2)
Delay recall	0/36 (0.05)	15/36 (5)
Executive function		
E-CFT		
Fragmentation	1/4 (11)	4/4 (100)
Planning	1/4 (5)	4/4 (100)
Perseveration	3/4 (12)	4/4 (100)
Word fluency		
Number of correct responses	16 (2)	35 (50)
Figure fluency		
Number of correct responses	37 (16)	42 (25)
Stroop test		
Response time	24 second (50)	21 second (63)

E-CFT: Executive-Complex Figure Test, K-AVLT: Korean-Auditory Verbal Learning Test.

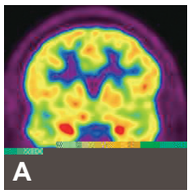

Fig. 2. Brain coronal ^{18}fluorodeoxy glucose-positron emission tomography (PET) revealed increased glucose metabolism in bilateral amygdala and parahippocampal gyrus (A, B, and C). Follow-up PET showed no findings in the same areas (D, E, and F).

gradually became worse. Three months earlier she had been diagnosed with SLE due to the presence of arthritis in her hands and knees, Raynaud phenomenon, positive antinuclear antibodies (ANA) and positive anti-dsDNA antibodies. There was no history of oral ulcers, malar or discoid rash, photosensitivity, cardio-pulmonary involvement, hair loss, neurologic disorders like seizures, and/or psychosis. She had no family history of either rheumatic or neurologic diseases. She denied smoking and did not consume alcohol. On admission, the patient had taken medications associated with SLE (prednisone 7.5 mg/day, hydroxychloroquine sulfate 300 mg/day). Her vital signs showed a mildly elevated body temperature (37.5°C), but were otherwise within normal limits. The physical examinations were unremarkable. Neurological examinations revealed anosmia, dysgeusia, and impairment of recent memory. She could not detect any scent in either nostril based on an olfactory recognition test, and she also felt that everything tasted sweet even if it was not. Her memory revealed severe impairment based on a three word recall test from the Mini-Mental State Examination (MMSE) (26/30).[5] Other neurological examinations showed unremarkable findings. Laboratory findings demonstrated the presence of positive ANA, anti-rheumatoid antibodies, and anti-ribonucleoprotein antibodies (>8.0 AI). Cerebrospinal fluid tests revealed mild pleocystosis with dominance of lymphocytes (white blood cell: 11, red blood cell: 0), but otherwise findings were within normal limits. We diagnosed her with NPSLE, and then we performed a brain MRI with contrast and more detailed neuropsychological tests. The brain MRI revealed unremarkable findings (Fig. 1) but the neuropsychological tests showed a marked decrease in immediate and delayed recall on the Rey-Kim Memory Test, and mild executive dysfunction on the Kims Frontal-Executive